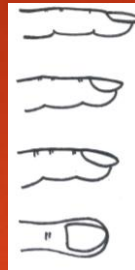

MRCPCH revision: Cardiovascular station - S Constantinou

- ▶ 0:00 Intro & overview
- ▶ 1:44 Top tips
 - ▶ Be opportunistic, Find a Cardio SpR to watch you, Palpate bilaterally for apex beat, Don't narrow differential too quickly.
- ▶ 2:30 Cardio exam overview
- ▶ 3:06 – WIPER
- ▶ 3:37 – Around the room: oxygen saturation probes, supplemental O₂
- ▶ 3:44 – Patient from end of bed: small for age, well grown, pink, pale or blue, dysmorphism, increased work of breathing
- ▶ 4:10 – Hands: cool or warm, clubbing, splinter haemorrhages, oslers nodes
- ▶ 4:32 – Radial pulse, Brachial pulse, Carotid pulse. No thumbs! Character at central pulses (not radial)
- ▶ 5:00 – Face: dysmorphism, conjunctival pallor, dental caries, central cyanosis
- ▶ 5:30 – Precordium: chest wall deformities, scars, visible impulses
- ▶ 6:00 Palpation: bilat for apex beat, heaves, thrills
- ▶ 6:23 Auscultation (briefly, further podcast about murmurs coming soon!)
- ▶ 7:10 – Last bits: Hepatomegaly, femorals, lung bases, peripheral / sacral oedema
- ▶ 7:45 – 'To complete my examination I would like to measure the HR, BP, O₂ sats & plot the height and weight on an appropriate chart.' (plus anything you forgot!)

▶ 8:20 Focus On: Clubbing



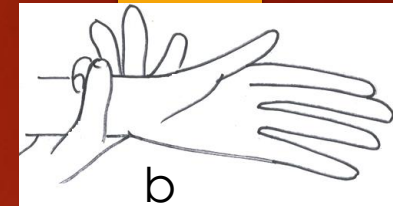
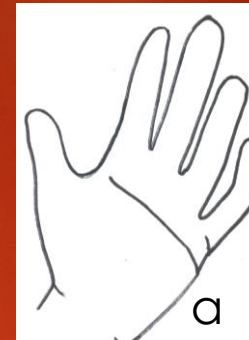Stages of Clubbing

Stage 1: normal appearance and angle but increased fluctuancy of nail bed

Stage 2: loss of angle between nail and nail bed

Stage 3: increase curvature of nail

Stage 4: expansion of terminal phalanx Drum stick appearance

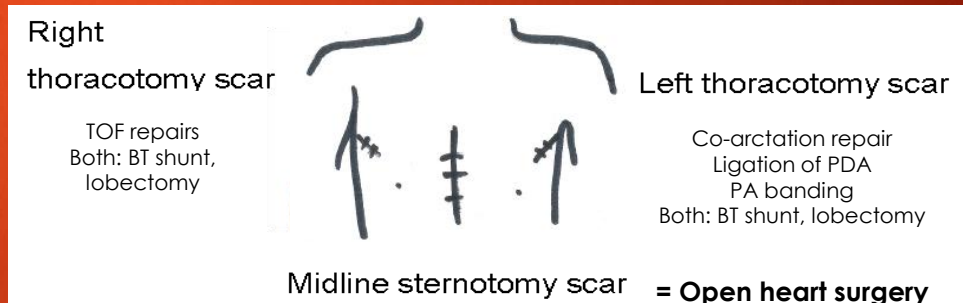


- ▶ 9:20 Focus On: Hand & Heart Defects
 - ▶ Turner's syndrome – short 4th, 5th metacarpals, hypoplastic nails
 - ▶ T21- clinodactyly, single palmar crease (a)
 - ▶ Marfan's syndrome – arachnodactyly (b)
 - ▶ VACTERL, Holt Oram, TAR – radial abnormalities

▶ 10:40 Focus on: Pulse

Collapsing	AR, PDA
Thready	Heart Failure
Asymmetrical	Pre or post coarctation repair
Slow rising	AS

▶ 12:20 Focus on: Scars



- ▶ Apex: forceful - cardiac myopathy, feeble - heart failure, displacement - dilated cardiomyopathy. Heave - palpable right ventricular impulse. Thrill - palpable murmur
- ▶ 16:50 Outro: PedZ app, Check out Pub Quiz!